

The Past 50 Years of Cardiovascular Surgery

Denton A. Cooley, MD; O.H. Frazier, MD

Cardiovascular surgery has developed so rapidly that it is hard to believe that this specialty is little more than a half-century old. In fact, had it not been for World War II, the emergence of modern cardiac surgery may have been delayed further. In 1943 and 1944, Dwight Harken,¹ then a captain in the medical corps, successfully removed foreign bodies from in and around the hearts of >100 soldiers who had been injured in battle. Harken's work helped overcome the notion that the heart could not be surgically manipulated and, not only did it pave the way for the incredible progress of the last 50 years, it was a catalyst for the event that would mark the dawn of this era: the creation of the first Blalock-Taussig shunt for treating tetralogy of Fallot in 1944.² The striking results from this procedure, which increased the circulation through the pulmonary arterial system, caused much excitement in the surgical community.

In those early days at the midpoint of the 20th century, many warned about operating on children, particularly those with cardiovascular disease, severe cyanosis, and hypoxia. There was great concern that it would not be possible to anesthetize these young patients safely and to see them through an operation. Helen Taussig believed that one should not try to operate on a child younger than 4 years with tetralogy of Fallot or a child younger than 8 years with an aortic coarctation. Many pediatricians heeded these warnings, and it was with enormous trepidation that the anesthesia staff undertook the first congenital heart operations in very young patients. (In the earliest days of heart surgery, nurse-anesthetists usually administered anesthesia.) However, this did not deter those who believed that successful cardiac surgery could be undertaken in younger patients. By 1959, those at Texas Children's Hospital had successfully operated on 120 infants with congenital defects.³

Advent of Open Heart Surgery

Until the mid-1950s, most pediatric operations were "palliative" extracardiac procedures performed on the closed heart. The challenge was to operate inside the heart safely and to perform a definitive intracardiac repair. A number of ingenious techniques were proposed for this purpose. For instance, Elton Watkins, a medical student at Harvard, suggested a procedure to Robert Gross that became known as the Gross atrial well.⁴ They showed that it was possible to operate inside of the beating heart, through a rubber funnel sutured to

an incision in the atrial wall, as long as the patient was heparinized. This technique, however, was rather traumatic to the surgeon's index finger: the only way a surgeon knew when the suture was properly placed was to impale his finger with the needle. That resulted in many painful fingers.

What was definitely needed was a method for interrupting blood flow during an intracardiac operation. Hypothermia was one of the early methods tried, either by placing patients in a tub of ice water or by cooling them with ice packs. Once the patient's temperature was lowered to $\approx 26^{\circ}\text{F}$, blood flow to the heart could be interrupted rather easily by placing a snare on the inferior and superior vena cava. If the repair could be accomplished within 8 or 10 minutes, the patient was spared cerebral complications. Unfortunately, this technique had some serious drawbacks, including the possibility of air embolism, which was one of the greatest problems encountered by the developers of open heart techniques. In addition, the more complicated lesions, such as atrioventricular canal and large ventricular septal defects, could not be repaired at all. Thus, it became increasingly obvious that more dependable methods were needed.

For over a decade, John Gibbon⁵ worked to design a device that would provide for the oxygenation and circulation of blood in an extracorporeal circuit. Finally, in 1953, his open heart technique with total cardiopulmonary bypass was tested in 4 patients with congenital heart disease, only one of whom survived. Although Gibbon called a personal halt to the clinical use of his technique, his efforts were a strong stimulus to other investigators.

The first truly successful open heart operations were performed by C. Walton Lillehei⁶ using a cross-circulation technique; this method had been performed as a physiological experiment for ≈ 50 years before the first trial in a child. This approach worked very well. One of the parents, usually the mother, served as the oxygenator. By cross-circulating the parent's arterial blood into the recipient and controlling the amount of venous blood being returned, the surgeon had up to an hour in which to perform an intracardiac repair. Proponents of this technique soon determined that the patient could survive if less than full cardiac output was used and, therefore, only moderate stress was placed on the donor. Lillehei said that it was the only operation he knew of with a potential 200% mortality rate, because both the donor and the recipient could be lost. (In Lillehei's experience, only 1 donor

From the Texas Heart Institute at St. Luke's Episcopal Hospital, Houston, Texas.

Correspondence and reprint requests to Dr Denton A. Cooley, Texas Heart Institute, PO Box 20345, Houston, TX 77225. E-mail dcooley@heart.thi.tmc.edu

(*Circulation*. 2000;102:IV-87-IV-93.)

© 2000 American Heart Association, Inc.

Circulation is available at <http://www.circulationaha.org>

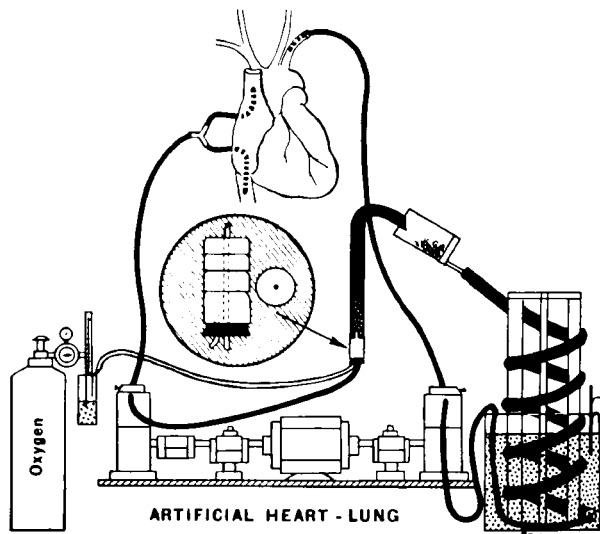


Figure 1. Drawing of the DeWall-Lillehei pump oxygenator. Reprinted with permission of the Texas Heart Institute.^{7b}

ever suffered a serious complication—a stroke that probably resulted from an air embolism.) With this approach, Lillehei and his team were able to correct ventricular septal defects and even tetralogy of Fallot. With the success of this method, he became convinced that open heart surgery with temporary cardiopulmonary bypass was feasible.

Among the different types of oxygenators being investigated, the one devised by one of Lillehei's younger colleagues, Richard DeWall,^{7a} proved the most practical (Figure 1). DeWall and his colleagues devised a simple bubble diffusion system, with a helical coil for defoaming the blood by means of a silicone antifoam substance. With this mechanical oxygenator and a pump in the circuit, open heart surgery finally became a reality. Many more complicated defects, such as tetralogy of Fallot, ventricular and atrial septal defects, and other intricate lesions, became amenable to surgical correction. Using the more complex Gibbon-type apparatus (Figure 2), John Kirklin at the Mayo Clinic also

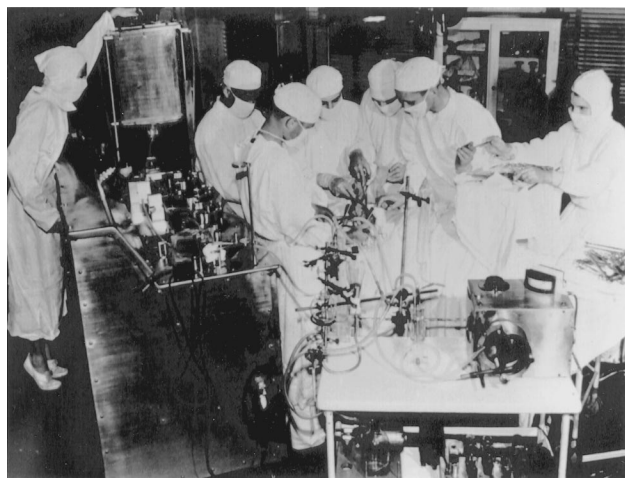


Figure 2. The Mayo-Gibbon heart lung machine. Reprinted with permission of the Texas Heart Institute.^{7b}




Figure 3. The modified DeWall-Lillehei pump oxygenator, which was first used at the Texas Heart Institute in 1956. Reprinted with permission of the Texas Heart Institute.^{7b}

demonstrated that open repair of complicated defects could be accomplished with low risk.⁸ Soon thereafter, our team at the Texas Heart Institute also adopted the DeWall-Lillehei device, which allowed us to establish an open heart program in 1955. We modified the DeWall device, however, by building a vertical stainless steel model that was easier to assemble and use (Figure 3). By the end of 1956, using this device and a roller pump (Figures 4 and 5), we had performed >100 open heart procedures, more than any other group in the world,⁹ including the first repair of a postinfarction ventricular septal defect¹⁰ (Figure 6).

One of the major problems associated with those early procedures was the need to prime the extracorporeal system with blood. Depending on the complexity of the system, up to 14 U of blood had to be collected on the morning of surgery, and the blood had to be freshly heparinized and kept at body temperature (Figure 7). With some of the larger extracorporeal systems, the operation could not be performed until 8 or 10 o'clock at night because it was difficult to collect so much blood. Eventually, we showed that blood could be stored overnight and that it could be citrated. Nonetheless, cardiac surgeons had become slaves of the blood bank with respect to the scheduling of open heart operations.

A major breakthrough came when Nazih Zudhi and colleagues¹¹ demonstrated that priming the extracorporeal circuit with blood was not only unnecessary, but potentially hazard-

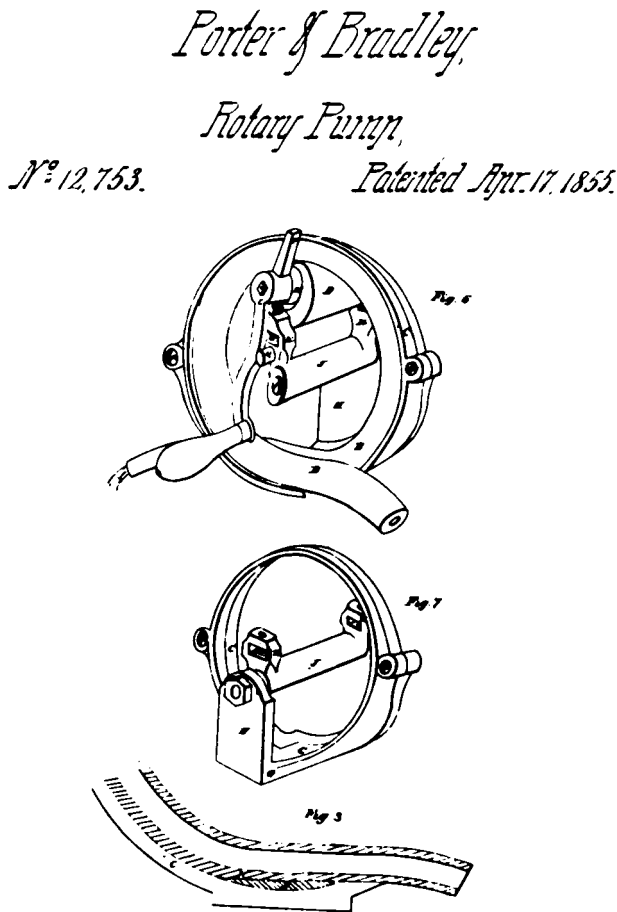


Figure 4. Drawing of an early roller pump, which was patented in 1855 by Porter and Bradley. Reprinted with permission of the Texas Heart Institute.^{7b}

ous. Our team next promoted and popularized the concept of hemodilution with 5% dextrose solution¹² and, although we had many critics, the critics were proved wrong. In this technique, which is used almost universally today, a disposable oxygenator primed with 5% dextrose was used with normothermia. For the first time, open heart surgery became practical. It also became safer because, when 6 or 8 U of blood are mixed together in an extracorporeal circuit, patients end the procedure with more transfused blood than their original volume. Also, because each unit of blood had some basic incompatibility with the others, some patients developed homologous blood syndrome, which contributed to various postoperative complications. With the introduction of a non-blood-priming technique, these concerns became relatively unimportant.

With these simplified techniques, surgeons were quickly able to extend their use of open heart surgery and to repair almost every type of intracardiac abnormality.

Valvular Repair and Replacement

The earliest intracardiac operations had been performed for rheumatic heart disease and mitral stenosis. Several surgeons, including Lord Brock,¹³ Charles Bailey,¹⁴ and Dwight Harken and colleagues,¹⁵ had shown that the stenotic mitral valve

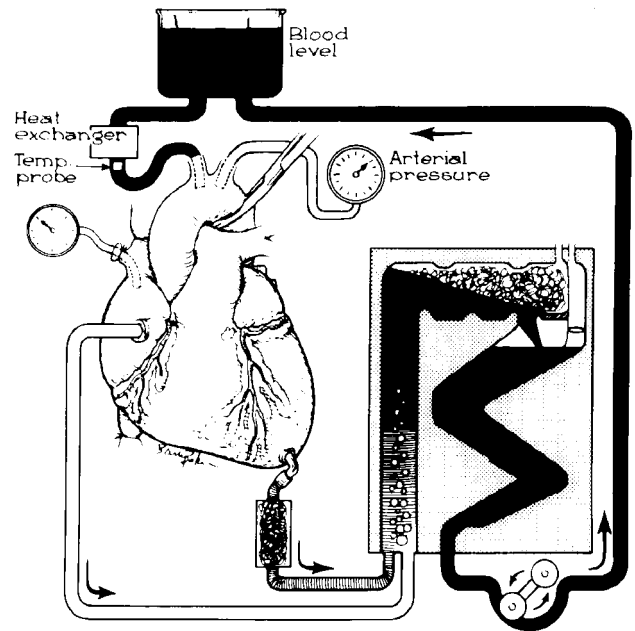


Figure 5. Drawing of the cardiopulmonary bypass circuit used with the heart-lung machine of the 1960s. Reprinted with permission of the Texas Heart Institute.^{7b}

could be manipulated in a technique called “finger-fracture” valvuloplasty. However, those who performed such procedures realized that, in many instances, they were not really accomplishing much. Even with a knife on the fingertip, this technique was not very effective. In 1954, the treatment of mitral valve stenosis was revolutionized with the advent of the mechanical dilator, a relatively simple device that was designed and first used by Charles Dubost.¹⁶ The dilator had 2 parallel blades that could be passed into the atrium and into the valve (Figure 8). Dilating the valve mechanically proved more effective than pulling it open manually. Today, cardiologists are using balloons, introduced through catheters in leg veins, for the same purpose. The approach seems to work well as a palliative measure.

Heart valve repair gave rise to a whole new field of possibilities, as well as a number of ingenious devices and techniques. In 1952, Hufnagel and Harvey¹⁷ introduced a valve that they had placed in a patient’s descending aorta to treat aortic regurgitation. Unfortunately, the silicone-type ball (methacrylate) was very resonant; if the patient opened his or her mouth, the clicking of the ball could be heard across a large room. Nevertheless, this valve did partially relieve aortic regurgitation by reducing left ventricular load by about one-third to one-half.

The real breakthrough was total valve replacement, which was introduced almost simultaneously by 2 surgeons: Dwight Harken,¹⁸ who used a double-caged, ball-and-seat prosthesis, and Albert Starr,¹⁹ who used a caged ball-and-seat valve. Both models incorporated a silastic ball within a metal cage. With the introduction of the ball-and-seat valve, surgeons could finally definitively treat aortic valve and mitral valve disease. Years of trial and error, however, were necessary before consistently durable, reliable valves would become available. Many of the pioneers of cardiac surgery worked to

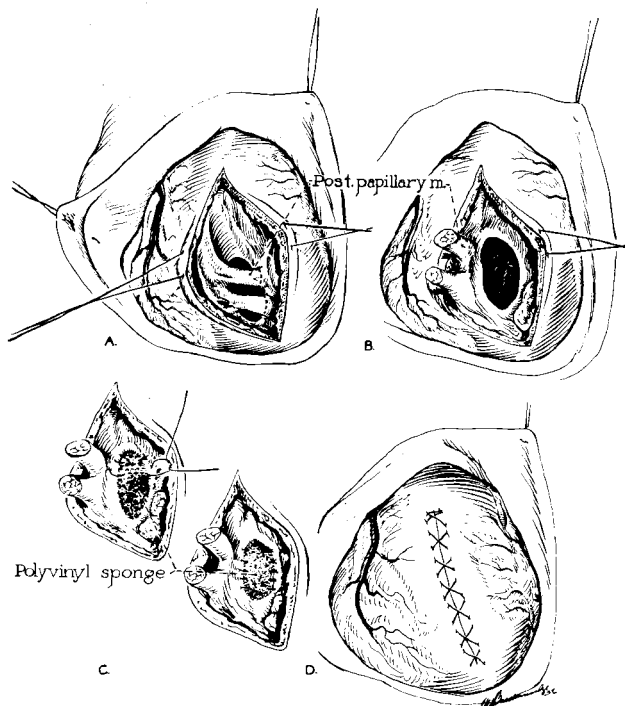


Figure 6. Technique used in the first repair of acute rupture of the interventricular septum. Reprinted with permission of the Texas Heart Institute.^{7b}

develop reliable prostheses, and they gave their names to the products that they developed: Smeloff, Magovern, Cromie, Braunwald, DeBakey, Barnard, Beall, Cross, Jones, Conrad, Kay, Starr, Taber, Cooley, Lillehei, Wada, Stuckey, Pierce, Behrendt, Morrow, Williams, Bjork, Gott, Emery, and Nicoloff, among others (Figure 9).

Even in cardiac surgery, techniques and procedures lose and gain fashion. For example, today's surgeons are now using homograft valves in an increasing number of cases. In earlier years, homografts never had the popularity that their mechanical counterparts did, in part because of the problems of supply and demand and of storage and preservation. Some,



Figure 7. Early operating room scene, showing the cumbersome pump oxygenator equipment and the 14 units of freshly drawn blood needed to repair a simple atrial septal defect. Reprinted with permission of the Texas Heart Institute.^{7b}

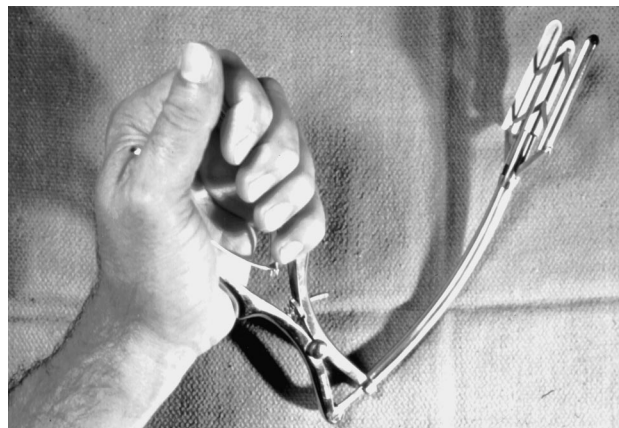

Figure 8. Dilator used in early commissurotomy procedures. Reprinted with permission of the Texas Heart Institute.^{7b}

however, continued to use homografts, especially Donald Ross²⁰ and Brian Barratt-Boyes,²¹ who were largely responsible for their development.

Even before valve prostheses became available, Ross²² conceived the idea of implanting a patient's own pulmonary valve as an autograft into the aortic annulus; he then replaced the pulmonary valve with a homograft or some other kind of valve. Today, there is renewed interest in the Ross procedure, and surgeons are even considering the use of mitral homografts to mimic normal function and eliminate the need for anticoagulation. Nevertheless, the natural valve should be retained whenever possible.

Coronary Revascularization

Patients with coronary artery disease comprise another group that challenged early cardiac surgeons. Originally, the only option was to modify or palliate this condition. Early operations were designed to stimulate intercoronary anastomoses by producing a granulomatous response in the pericardium and epicardium. To achieve this goal, powdered asbestos, talc, silica, or phenol was insufflated into the pericardial space. Other approaches included abrading the epicardium, ligating the internal mammary artery or coronary vein,

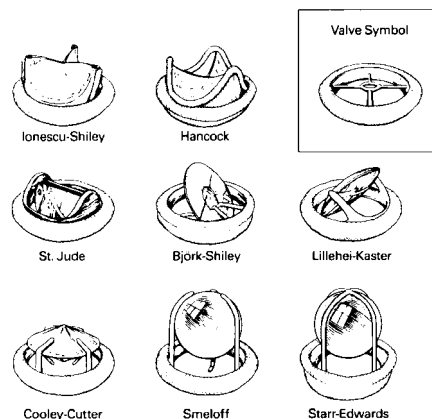


Figure 9. Examples of valves developed for valvular replacement operations.

arterializing the coronary sinus, or grafting vascular tissue into the epicardium.

A major breakthrough occurred with the advent of coronary arteriography, which allowed surgeons to visualize the coronary lesion for the first time. This breakthrough was brought about fortuitously in 1958 by Sones and Shirey,²³ who were attempting to perform a left ventriculogram in a patient and inadvertently injected a contrast agent into the patient's coronary circulation. Sones was terrified that the patient would not survive because, at that time, coronary injection was mistakenly considered dangerous. Sones subsequently designed and successfully used a specialized coronary catheter for selective coronary angiography.

Once surgeons could see where a coronary blockage was located, they could proceed with revascularization by means of a bypass graft technique. With cardiopulmonary bypass and cardioplegic arrest, surgeons were able to construct coronary bypass grafts in a quiet, bloodless field, originally by using saphenous vein grafts and later by including the internal mammary artery. The first coronary bypass was performed by Edward Garrett and colleagues²⁴ in 1964, when they encountered difficulties while performing an endarterectomy and were forced to bypass the left anterior descending artery. Much of the pioneering work in the area of coronary bypass was done by René Favaloro and Donald Effler and colleagues,²⁵ who were the first to report the procedure, and by Dudley Johnson and Derward Lepley and colleagues,²⁶ beginning in late 1968. The procedure soon became the world's most frequently performed cardiac operation.

After the introduction of percutaneous transluminal coronary angioplasty by Andreas Gruentzig and colleagues,²⁷ the use of interventional techniques increased, and the number of surgical revascularization procedures began to decline. At the Texas Heart Institute and at most other heart centers, patients with coronary artery disease now undergo more interventional procedures than direct surgical operations. However, the pendulum may swing the other way again. The results of simple beating-heart surgery are so satisfactory that surgeons can almost offer patients the same degree of comfort, and perhaps a better life expectancy, by performing an internal mammary artery bypass in a minimally invasive procedure rather than by an interventional procedure.

Many surgeons today are reverting to operating on the beating heart. Because coronary artery bypass grafting is done on the surface of the heart, cardiopulmonary bypass is not absolutely essential. Moreover, the extracorporeal circuit (particularly the oxygenators and suction devices) can induce a whole-body inflammatory response and other postoperative complications, which are eliminated by beating-heart surgery. One of the most difficult problems in developing this technique has been in finding methods to stabilize the arteries during grafting. New devices are being developed, however, to make such procedures safer and more reliable (Figure 10).

Despite the success of conventional myocardial revascularization techniques, some patients are not suitable candidates for these therapies, so researchers have continued to look for new options. Surgeons have begun to use lasers to perform a procedure called transmyocardial laser revascularization. The laser creates new channels through which oxy-

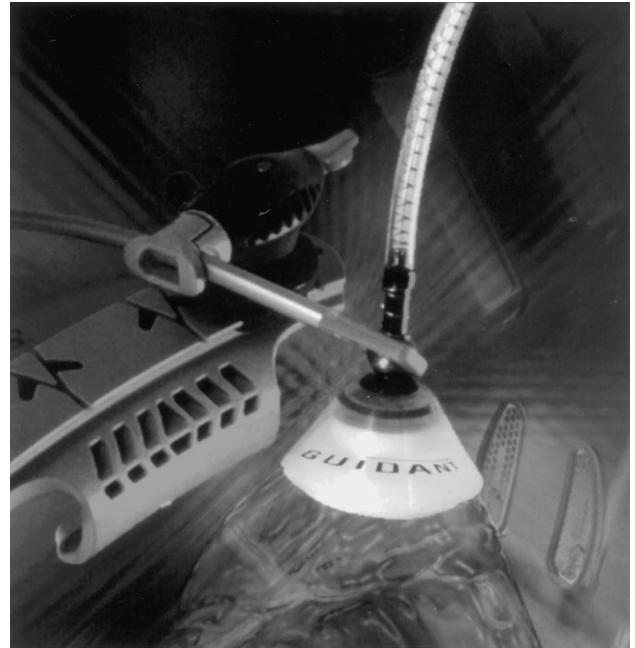


Figure 10. Example of a stabilizer used for beating heart surgical procedures. Reprinted with permission, Guidant Corp.

genated blood can enter the myocardium from the intracavitary region.²⁸ Controversy exists, however, regarding the mechanism of transmyocardial laser revascularization and the likelihood of the channels' remaining patent. Whatever its mechanism, this technique may stimulate angiogenesis, thereby revascularizing the ischemic myocardium. Thus far, it remains unclear whether the promising results are related to subjective factors or to actual myocardial revascularization.

Aneurysm Repair

Aneurysm surgery has evolved in a fashion similar to coronary surgery, in that various indirect methods were used for some years until excision was undertaken and, later, repair became standard. In 1951, at the annual meeting of the Southern Surgical Society, Cooley and DeBakey became the first to recommend direct surgical removal of aortic aneurysms. Synthetic vascular grafts were not yet available, so the early operations were performed mainly on sacciform aneurysms, many of which were luetic in origin. After fabric vascular grafts became available in the late 1950s, the goal became to restore circulation without excision of the lesion.

Cardiac Support and Replacement

Probably the most exciting event in heart surgery occurred in 1967, when a South African surgeon named Christiaan Barnard²⁹ performed the first human heart transplant. The operation was only temporarily successful, but it was an important historic event. Although Barnard was roundly criticized at the time by ethicists and religious groups, both of whom opposed the very concept of heart transplantation, many surgeons around the world were searching for the means to perform a heart transplant. It was Barnard, however, who defined for the rest of the world the concept of brain

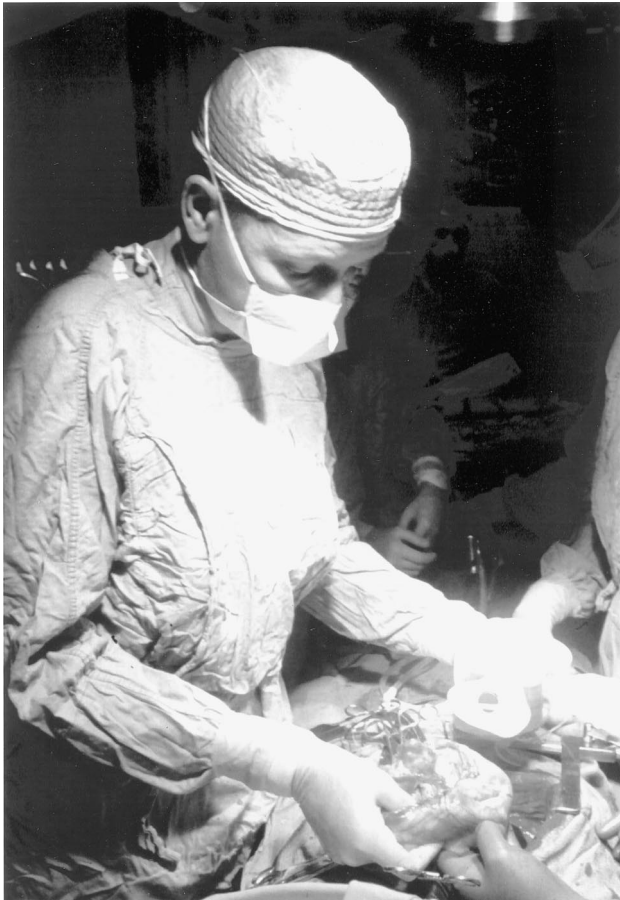

Figure 11. First bridge-to-transplant operation in 1969. The bridge used was the Liotta total artificial heart. Reprinted with permission of the Texas Heart Institute.^{7b}

death and who deserves credit for making heart transplantation a reality.

Soon after Barnard's transplant, the Texas Heart Institute became actively involved in cardiac transplantation. Within a year, surgeons here had performed 20 transplant operations, which put the Institute in the forefront of cardiac transplantation in the world.³⁰ Unfortunately, none of those 20 patients lived more than 18 months: they all succumbed to rejection and infection. We, and others, became discouraged, and a moratorium was called on any further cardiac transplant procedures. In 1980, however, Barry Kahan³¹ introduced the new immunosuppressant cyclosporine, which he used to prevent rejection in renal transplant patients. With his permission and encouragement, we began using cyclosporine to prevent rejection in heart transplant patients. The introduction of cyclosporine gave surgeons the tool they needed to re-enter the field of cardiac transplantation. Shumway and colleagues³² maintained a determined interest in the field of cardiac transplantation during the precyclosporine era, and they demonstrated the logistics of organ procurement.

During this time, investigators were developing a mechanical means of supporting the failing heart. One possibility, a total artificial heart, was being developed by Domingo Liotta in our laboratory. In 1969, we³³ used this heart in the first bridge-to-transplant operation (Figure 11) for a patient who

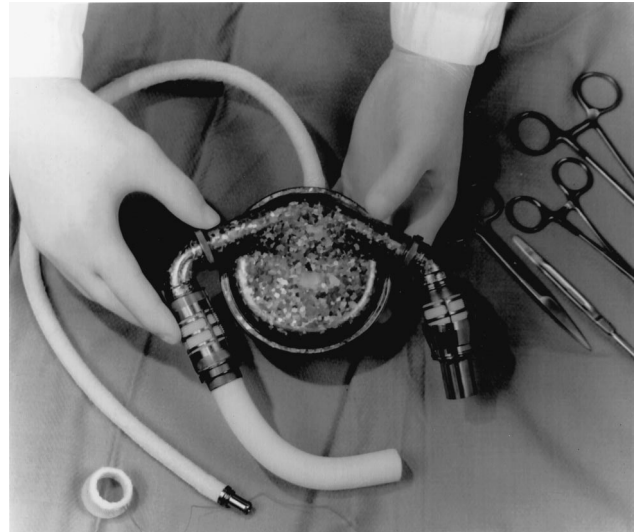


Figure 12. HeartMate left ventricular assist device. Reprinted with permission of the Texas Heart Institute.^{7b}

could not be weaned from cardiopulmonary bypass after an extensive ventricular reduction procedure (what would be called the Batista³⁴ procedure today). Three days after the artificial heart was implanted (the first implantation of its kind in the world), a donor was found, and a heart transplant operation was performed. Today, the bridge-to-transplant operation has become a routine procedure, with a variety of circulatory support devices available for use as a bridge.

The left ventricular assist device is most commonly used today as a bridge to transplant. In a 1980 request for a proposal, the National Heart, Lung, and Blood Institute changed its focus from the total artificial heart program to support development of left ventricular assist devices. A number of devices resulted from that development program. One such device, the HeartMate left ventricular assist device (Thermo Cardiosystems, Woburn, MA), was the first fully implantable device to receive approval from the US Food and Drug Administration for implantation in humans as a bridge to transplant (Figure 12). The HeartMate connects the left ventricle to the ascending aorta. By unloading the left ventricle, the pump allows the heart to rest and is proven to help in the recovery of at least some left ventricular function in most patients.³⁵ Because of the possibility of recovery and its track record for reliability, the HeartMate device is now being tested in a controlled trial for long-term use.

Newer still are much smaller, continuous-flow pumps. One of several under investigation is the Jarvik 2000, which is being developed at the Texas Heart Institute with Robert Jarvik.³⁶ The device is implanted into the apex of the left ventricle and rests in an intracavitary position, which makes it very different from earlier left ventricular assist devices (Figure 13). The Jarvik 2000 shows promise as a bridge to transplant and as long-term support for the heart; however, in the United States, the Food and Drug Administration currently restricts its use to a bridge. The device has been implanted in 7 patients. Two of these patients have recently undergone transplant operations and are doing well. In



Figure 13. Jarvik 2000 continuous-flow left ventricular assist device. Reprinted with the permission of the Texas Heart Institute.^{7b}

Oxford, England, the Jarvik system was implanted for long-term support in 2 nontransplant candidates.

Summary

Cardiac surgery has undergone a rapid and extraordinary development during the past 50 years. Many operations that were once considered experimental are now routine, and thousands of open heart procedures are performed each year. In 1997, in the United States alone, surgeons performed 197 000 cardiovascular procedures, including 2300 heart transplant operations. These statistics are astonishing to both Dr Cooley, who began practicing >50 years ago, and Dr Frazier, who began practicing 30 years ago. Even with this increased practice, cardiac surgery remains what it has always been: a profession where art and science mix and where skill and decisiveness rule; these qualities are unlikely to change any time soon. The use of robotics for minimally invasive procedures and the minimally invasive procedures themselves can challenge even the deftest of hands and may subject the patient to added risk. Technology has certainly provided a new dimension to the practice of cardiovascular surgery; in our haste to embrace the future, however, we must not forget that we should be building on our past.

References

- Harken DE. Foreign bodies in, and in relation to, thoracic blood vessels and heart. I: techniques for approaching and removing foreign bodies from chambers of heart. *Surg Gynecol Obstet.* 1946;83:117–125.
- Blalock A, Taussig HB. The surgical treatment of malformations of the heart in which there is pulmonary stenosis or pulmonary atresia. *JAMA.* 1945;128:189–202.
- Collins HA, Harberg FJ, Soltero LR, et al. Cardiac surgery in the newborn: experience with 120 patients under one year of age. *Surgery.* 1959;45:506–519.
- Gross RE, Watkins E. Surgical closure of atrial septal defects. *Arch Surg.* 1953;67:676–685.
- Gibbon JH. Application of a mechanical heart and lung apparatus to cardiac surgery. *Minn Med.* 1954;37:171–180.
- Lillehei CW. Controlled cross circulation for direct-vision intracardiac surgery: correction of ventricular septal defects, atrioventricularis communis, and tetralogy of Fallot. *Postgrad Med J.* 1955;1:388–396.
- DeWall RA, Warden HE, Read RC, et al. A simple, expendable, artificial oxygenator for open heart surgery. *Surg Clin North Am.* 1956;36:1025–1034.
- Texas Heart Institute Foundation. *Twenty-five Years of Excellence: A History of the Texas Heart Institute.* Houston, Tex: Texas Heart Institute Foundation, 1989.

- Kirklin JW, DuShane JW, Patrick RT. Intracardiac surgery with the aid of a mechanical pump-oxygenator system (Gibbon type): report of eight cases. *Mayo Clin Proc.* 1955;30:201–206.
- Cooley DA, Castro-Villagrana B, DeBakey ME, et al. Use of temporary cardiopulmonary bypass in cardiac and aortic surgery: report of 134 cases. *Postgrad Med.* 1957;22:479–484.
- Cooley DA, Belmonte BA, Zeis LB, et al. Surgical repair of ruptured interventricular septum following acute myocardial infarction. *Surgery.* 1957;41:930–937.
- Zuhdi N, McCollough B, Carey J, et al. Hypothermic perfusion for open heart surgery procedures: report of the use of a heart lung machine primed with five percent dextrose in water inducing hemodilution. *J Int Coll Surg.* 1961;35:319–326.
- Cooley DA, Beall AC Jr, Grondin P. Open heart operations with disposable oxygenators, five percent dextrose prime, and normothermia. *Surgery.* 1962;52:713–719.
- Brock RC. The surgery and pathological anatomy of the mitral valve. *Br Heart J.* 1952;14:489–513.
- Bailey CP. Surgical treatment of mitral stenosis (mitral commissurotomy). *Dis Chest.* 1949;15:377–97.
- Harken DE, Ellis LB, Ware PF, et al. The surgical treatment of mitral stenosis, I: valvuloplasty. *N Engl J Med.* 1948;239:801–809.
- Dubost C. Presentation d'un nouvel instrument dilateur pour commissurotomie mitrale. *Presse Med.* 1954;62:253.
- Hufnagel CA, Harvey WP. The surgical correlation of aortic regurgitation: a preliminary report. *Bull Georgetown Univ Med Cent.* 1952;6:60–61.
- Harken DE, Soroff HS, Taylor WJ, et al. Partial and complete prostheses in aortic insufficiency. *J Thorac Cardiovasc Surg.* 1960;40:744–762.
- Starr A. Total mitral replacement: fixation and thrombosis. *Surg Forum.* 1960;11:258–260.
- Ross D. Homograft replacement of the aortic valve. *Lancet.* 1962;2:487–488.
- Brratt-Boyes BG. A method for preparing and inserting a homograft aortic valve. *Br J Surg.* 1965;52:847–856.
- Ross DN. Replacement of aortic and mitral valves with pulmonary autograft. *Lancet.* 1967;2:956–958.
- Sones FM, Shirey EK. Cine coronary arteriography. *Mod Concepts Cardiovasc Dis.* 1962;31:735–738.
- Garrett HE, Gartmill TB, Thiele JP, et al. Experimental evaluation of venous autografts as aorta to left ventricular myocardial shunts in revascularization of the heart: a preliminary report. *Cardiovasc Res Cent Bull.* 1964;3:15–20.
- Favaloro RG, Effler DB, Groves LK, et al. Severe segmental obstruction of the left main coronary artery and its divisions: surgical treatment by the saphenous vein graft technique. *J Thorac Cardiovasc Surg.* 1970;60:469–482.
- Johnson WD, Flemma RJ, Lepley D Jr, et al. Extended treatment of severe coronary artery disease: a total surgical approach. *Ann Surg.* 1969;170:460–470.
- Gruntzig AR, Senning A, Siegenthaler WE. Nonoperative dilatation of coronary-artery stenosis: percutaneous transluminal coronary angioplasty. *N Engl J Med.* 1979;301:61–68.
- Frazier OH, March RJ, Horvath KA. Transmyocardial revascularization with a carbon dioxide laser in patients with end-stage coronary artery disease. *N Engl J Med.* 1999;341:1021–1028.
- Barnard CN. The operation: a human cardiac transplant: an interim report of a successful operation performed at Groote Schuur Hospital, Cape Town. *S Afr Med J.* 1967;41:1271–1274.
- Cooley DA, Bloodwell RD, Hallman GL, et al. Organ transplantation for advanced cardiopulmonary disease. *Ann Thorac Surg.* 1969;8:30–46.
- Kahan BD, Kerman RH, Wideman CA, et al. Impact of cyclosporine on renal transplant practice at the University of Texas Medical School at Houston. *Am J Kidney Dis.* 1985;5:288–295.
- Jamieson SW, Stinson EB, Shumway NE. Cardiac transplantation in 150 patients at Stanford University. *BMJ.* 1979;1:93–95.
- Cooley DA, Liotta D, Hallman GI, et al. Orthotopic cardiac prosthesis for two-staged cardiac replacement. *Am J Cardiol.* 1969;24:723–730.
- Batista RJV, Santos JLV, Takeshita N, et al. Partial left ventriculectomy to improve left ventricular function in end-stage heart disease. *J Card Surg.* 1996;11:96–97.
- Frazier OH, Benedict CR, Radovancevic B, et al. Improved left ventricular function after chronic left ventricular unloading. *Ann Thorac Surg.* 1996;62:675–681.
- Westaby S, Katsumata T, Houel R, et al. Jarvik 2000 heart: potential for bridge to myocyte recovery. *Circulation.* 1998;98:1568–1574.

KEY WORDS: heart diseases ■ surgery ■ cardiopulmonary bypass

The Past 50 Years of Cardiovascular Surgery Denton A. Cooley and O. H. Frazier

Circulation. 2000;102:Iv-87-Iv-93

doi: 10.1161/01.CIR.102.suppl_4.IV-87

Circulation is published by the American Heart Association, 7272 Greenville Avenue, Dallas, TX 75231

Copyright © 2000 American Heart Association, Inc. All rights reserved.

Print ISSN: 0009-7322. Online ISSN: 1524-4539

The online version of this article, along with updated information and services, is located on the
World Wide Web at:

http://circ.ahajournals.org/content/102/suppl_4/Iv-87

Permissions: Requests for permissions to reproduce figures, tables, or portions of articles originally published in *Circulation* can be obtained via RightsLink, a service of the Copyright Clearance Center, not the Editorial Office. Once the online version of the published article for which permission is being requested is located, click Request Permissions in the middle column of the Web page under Services. Further information about this process is available in the [Permissions and Rights Question and Answer](#) document.

Reprints: Information about reprints can be found online at:
<http://www.lww.com/reprints>

Subscriptions: Information about subscribing to *Circulation* is online at:
<http://circ.ahajournals.org/subscriptions/>